



Oral Manifestations in Ellis-van Creveld Syndrome: Report of Five Cases

Abel Cahuana, PhD, MD, DDS Camila Palma, DDS Wilber Gonzáles, DDS Esther Geán, MD

Dr. Cahuana is associate doctor in the Pediatric Dentistry and Orthodontics Service, Drs. Palma and Gonzáles are interns, University of Barcelona, interns at the Hospital Sant Joan de Déu; Dr. Geán is associate doctor in the Genetic Section, Hospital Sant Joan de Déu, Barcelona, Spain.

Correspond with Dr. Cahuana at acahuana@hsjdbcn.org

Abstract

Ellis-van Creveld syndrome, or chondroectodermal dysplasia, is an autosomal recessive disorder with characteristic clinical manifestations. Its incidence in the general population is low. The oral manifestations of Ellis-van Creveld are found in soft tissues and teeth, but the dental literature on the subject is scarce. In the last 20 years, 5 cases of Ellis-van Creveld syndrome have been followed at the Pediatric Dentistry Service of the Hospital Sant Joan de Déu, Barcelona. The present study describes the constant and variable oral findings in these patients, which play an important role in the diagnosis criteria for the syndrome. The presence of a great variety of oral manifestations such as fusion of the upper lip to the gingival margin, presence of multiple frenula, abnormally shaped and microdontic teeth, and congenitally missing teeth requires multidisciplinary dental treatment, with consideration for the high incidence of cardiac defects in these patients. (*Pediatr Dent.* 2004;26:277-282)

KEYWORDS: CHONDROECTODERMAL DYSPLASIA, POLYDACTYLY, NEONATAL DWARFISM, CONGENITAL HEART DISEASE

Received March 27, 2003 Accepted August 20, 2003

Ellis-van Creveld syndrome (EvC) is an autosomal recessive chondroectodermal dysplasia, described by Richard Ellis and Simon van Creveld in 1940. The syndrome had been partially described earlier in several reports,¹ but it was Ellis and van Creveld's work that defined it. In 1964, McKusick et al² reported a large number of cases in the Amish community of Lancaster, Pa. Today, the syndrome has been described in other populations and it is known that it can affect all races.^{3,4}

EvC presents a characteristic tetrad:⁵

1. disproportionate dwarfism due to chondrodysplasia of the long bones and an exceptionally long trunk. The severity of short limbs increases from the proximal to the distal portions;
2. bilateral postaxial polydactyly of the hands, with the supernumerary finger usually being on the ulnar side. Occasionally a supernumerary toe may be present;
3. ectodermal dysplasia with dystrophic, small nails, thin sparse hair, and hypodontic and abnormally formed teeth;
4. congenital heart malformations in 50% to 60% of cases, the most common being a single atrium and a ventricular septal defect.

Other skeletal anomalies such as genu valgum (knock knees) have occasionally been reported.⁶ Patients' intelligence is usually normal.⁷⁻⁹

EvC is a generalized dysplasia of endochondral ossification¹⁰ caused by mutations in a novel gene on chromosome 4p16, EVC. Heterozygous carriers of these mutations do not exhibit manifestations of the disorder.¹¹ Recently, a second gene that gives rise to the same phenotype of the syndrome has been identified, and named EVC2.¹² Affected individuals with mutations in EVC or EVC2 have the typical spectrum of features and are phenotypically indistinguishable. There is parental consanguinity in 30% of the cases.⁴ The prevalence outside the Amish community is 7/1,000,000,⁵ and there are some 300 reported cases in the literature.¹ The Amish of Lancaster account for 52.²

Before identification of the EvC genes, prenatal diagnosis could only be considered in the case of ecographic findings in families with a history of the condition.^{13,14} Today, a prenatal diagnosis can be made based on genetic molecular studies of the first subject and his or her parents.

Oral manifestations in Ellis-van Creveld syndrome are remarkable and constant.¹⁵ The most common finding is

Table 1. General Clinical Characteristics*

Clinical cases	1	2	3	4	5	%
Sex	F	M	F	F	F	80% F
Race	Caucasian	Arab	Caucasian	Caucasian	Caucasian	–
Family history	N	N	N	N	N	0
Parental consanguinity	N	Y	N	N	N	20
Dwarfism	Y	Y	Y	Y	Y	100
Polydactyly (hands or feet)	Y	Y	Y	Y	Y	100
Syndactyly	Y	Y	N	Y	N	60
Dystrophic nails	Y	Y	Y	Y	Y	100
Ectodermal dysplasia	Y	Y	Y	Y	Y	100
Cardiac defect	Y	Y	N	N	N	40
Normal intelligence	Y	Y	Y	Y	Y	100
Genu valgum	N	Y	N	N	N	20

*F=female; M=male; Y=yes; N=no.

Table 2. Oral Manifestations*

Clinical cases	1	2	3	4	5	%
Age at first dental visit	1	6	7	9	8	–
Years of dental control	4	6	11	6	9	–
Fusion of upper lip to gingival margin	Y	Y	Y	Y	Y	100
Multiple frenula	Y	Y	Y	Y	Y	100
Serrated alveolar ridge	N	N	N	Y	N	20
Abnormalities in tooth eruption						
Retarded eruption	Y	N	Y	Y	N	60
Abnormalities in number of teeth						
Congenitally missing teeth (primary or permanent)	Y	Y	Y	Y	Y	100
Supernumerary teeth	N	N	Y	N	Y	40
Abnormalities in shape of teeth						
Conical or abnormal teeth	Y	Y	Y	Y	Y	100
Molars with atypical grooves or cusps	Y	Y	Y	Y	Y	100
Microdontia	Y	N	Y	Y	Y	80
Dental fusion	Y	N	N	N	N	20
Dysmorphic/conical shaped roots	N	N	Y	Y	N	40

*Y=yes; N=no.

a fusion of the anterior portion of the upper lip to the maxillary gingival margin, so that no mucobuccal fold exists, causing the upper lip to present a slight V-notch in the middle.¹ The anterior portion of the lower alveolar ridge is often serrated, and multiple small labial frenula are frequent.^{1,8,16} Teeth tend to be small and conical, molars have abnormal cusps or accessory grooves,⁸ and sometimes hypoplastic enamel is seen.¹ Congenitally missing primary and permanent teeth,^{1,5,8} presence of supernumerary teeth,^{8,15} natal and neonatal teeth,^{1,8} dysmorphic conical-shaped

roots,¹⁶ and delay in eruption¹⁵ have also been reported. Malocclusions occur secondary to these oral abnormalities as they are of no specific type.¹⁷

Cardiac defects present in some EvC patients and require antibiotic coverage for the prevention of infectious endocarditis.⁵ Almost half of these patients die during childhood because of cardiorespiratory complications¹³; for this reason, the life expectancy of EvC patients is determined by their congenital cardiac disease.⁷

As of March 2003, nearly 200 articles have been published on EvC syndrome, of which only 20 have appeared in dental journals. Of these, a total of 17 cases describe oral manifestations. The objective of the present study is to describe the oral manifestations of EvC syndrome in a clinical series.

Description of cases

A retrospective study of patients diagnosed with chondroectodermal dysplasia or EvC syndrome seen at the Pediatric Dentistry and Orthodontic Service of the Hospital Sant Joan de Déu (HSJD), Barcelona, during the last 20 years was performed. The sample comprised of 5 patients with EvC, 4 female and 1 male, ages 1 to 9 years, followed for an average of 7.2 years (range=4-11 years). General clinical characteristics are shown in Table 1. Oral manifestations are presented in Table 2. Figures 1 to 11 show some of the general and oral clinical characteristics in these patients.

The dental management of these patients is presented in Table 3.

Discussion

Chondroectodermal dysplasia or EvC syndrome is an autosomal recessive disease. Its incidence is low, and it has been recorded in all races.⁴ At this institution, 5 cases were seen; only 1 was born at this hospital from a total of 52,501 births in the last 20 years (1982-2002). This case has been previously reported.⁷

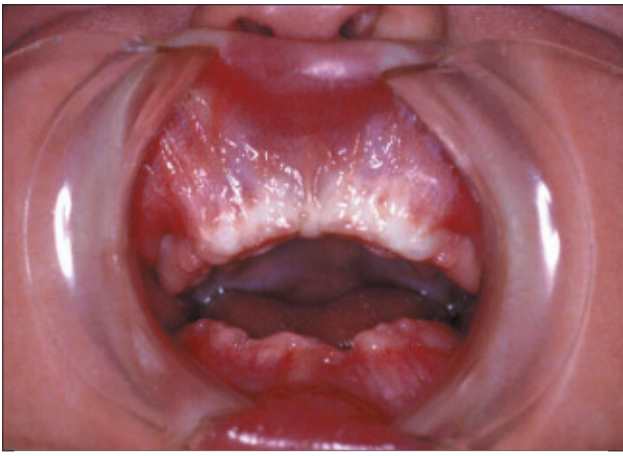

Figure 1. Newborn with irregular inferior alveolar ridge and underdeveloped multiple labial frenula.

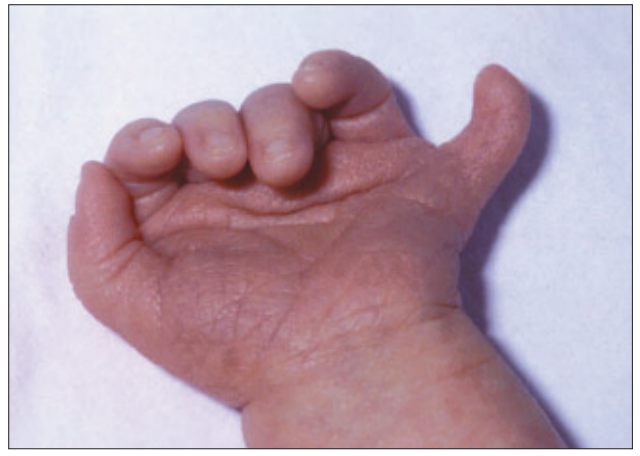

Figure 2. Detail of hand: polydactyly on the ulnar side and dystrophic nails.

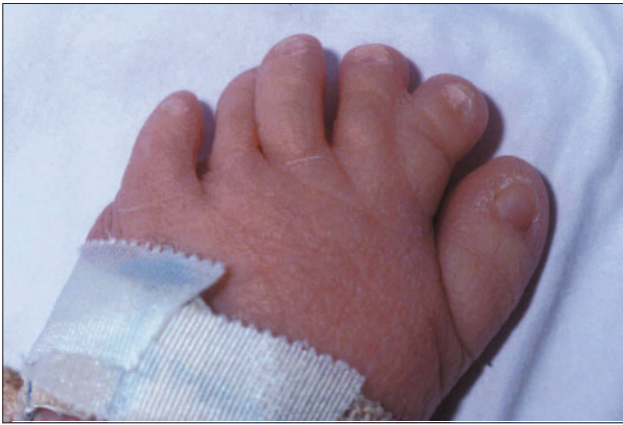

Figure 3. Detail of foot: syndactyly between the second and third toes and dystrophic nails.

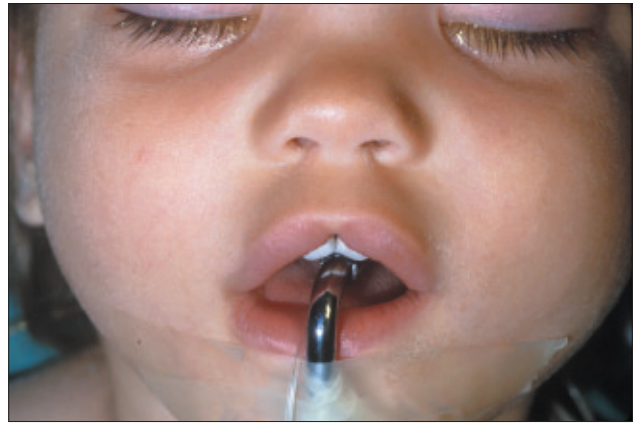

Figure 4. Detail of V-notch in the middle of the upper lip due to fusion of the anterior portion of the upper lip to the maxillary gingival margin.

The disease has characteristic oral manifestations that help early diagnosis at birth or during early childhood. Certain alterations become more noticeable during the subject's development. Oral manifestations are diverse, and involve not only soft tissues but also the number, shape, and structure of the teeth. The percentages of these manifestations are reflected in the present series, the most important being:

1. fusion of the upper lip to the gingival margin;
2. presence of multiple frenula;
3. conical, microdontic teeth;
4. molars with wide grooves and atypical cusps;
5. congenitally missing teeth.

In this study, hypodontia was observed in the upper and lower anterior portion in 80% of the cases, in agreement with previous reports.^{5,8,15-18} All patients but one were seen at later stages of their development, and there was no information available on the presence of natal or neonatal teeth.

The understanding of heredity has been aided by recent studies in genetics. McKusick² concluded that there appeared to be no heterozygous manifestations in EvC.

However, later publications^{19,20} demonstrated that the condition is clinically variable, which leads to a clinical picture that is not always complete. The condition's oral manifestations are also variable. Subjects exhibit major or constant manifestations such as fusion of the upper lip, multiple frenula, hypodontia, and atypically shaped teeth, and minor or variable manifestations such as retarded eruption, supernumerary teeth, dental fusion, dysmorphic roots, and taurodontism.

The dentist must be aware of the variety of oral manifestations present in the EvC syndrome to confirm the diagnosis and correct the defects as far as possible. The approach to dental management will depend on each particular case, and will require a multidisciplinary approach^{5,8,18} (Table 3).

Regarding conservative dental management, different types of treatments were realized in this series. The atypical occlusal anatomy of molars, with characteristic wide grooves, will not require fissure sealants in all cases. However, to prevent the development of caries, preventive measures such as dietary counseling, plaque control, oral hygiene instructions, and application of fluoride varnish or daily fluoride mouthrinses

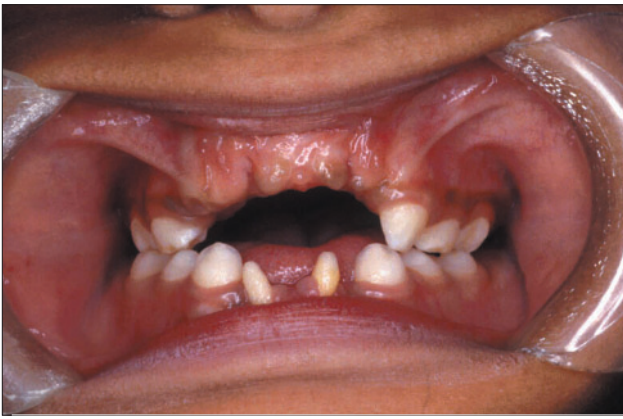

Figure 5. Front view showing multiple congenitally missing anterior teeth and small conical shaped lower incisors. Serration of the alveolar ridge in the anterior portion.

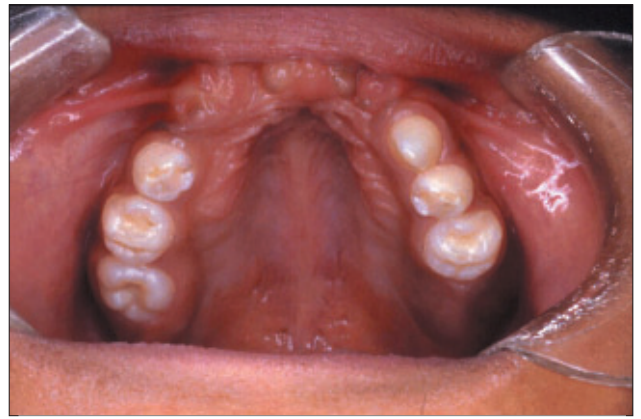


Figure 6. Occlusal upper view showing anterior hypodontia. Primary molars with wide grooves and atypical cusps.

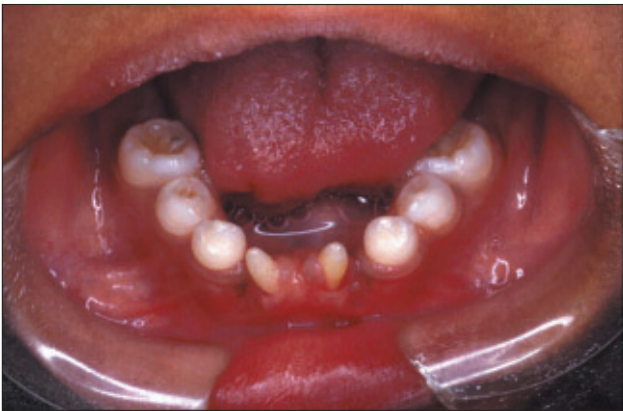

Figure 7. Occlusal lower view showing conical and microdontic incisors and congenitally missing lateral incisors. Atypical primary molars.

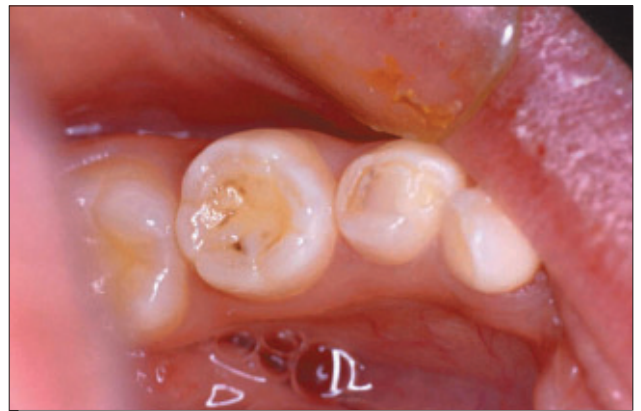

Figure 8. Detail of lower left second primary molar: wide central groove. The primary canine exhibits a talon cusp.

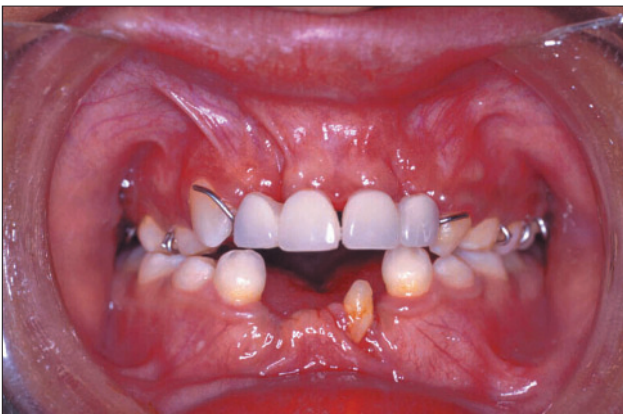

Figure 9. Upper anterior acrylic partial denture to maintain space and improve mastication, esthetics, and speech.

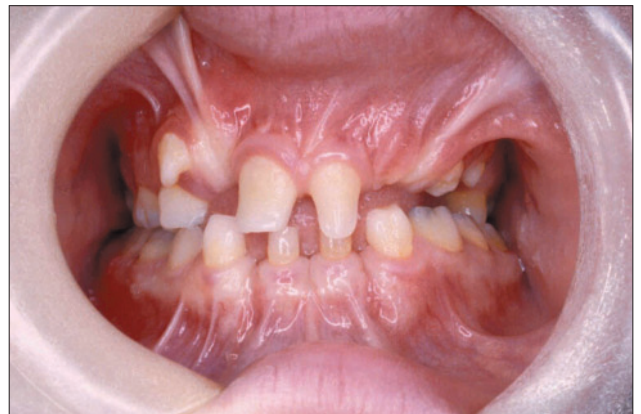

Figure 10. Multiple upper and lower labial frenula, congenitally missing lateral incisors, abnormally shaped upper incisors, and microdontic lower incisors.

should be taken.^{5,16} Carious teeth can be restored with glass ionomer, amalgam, or composites,^{5,8,16} always taking into account the possible presence of enlarged pulp chambers (taurodontism).⁸ To modify abnormally shaped teeth, crown or composite build-ups may be necessary,⁸ particularly microdents. Due to congenitally missing teeth, esthetic and

functional measures during the growth period include the use of anterior acrylic partial dentures to maintain space, and improve mastication, esthetics, and speech.^{5,18} Malocclusions are common in EvC syndrome. These patients may need orthodontic treatment,¹⁷ although surgical treatment has been used to solve skeletal abnormalities.¹⁸

In adulthood, these patients will likely require implants and prosthetic rehabilitation to replace congenitally missing teeth.

Conclusions

Throughout the management of EvC subjects, the dentist must bear in mind the high prevalence of cardiac defects in these patients and implement established procedures for the prevention of bacterial endocarditis when necessary.

References

1. Atasu M, Biren S. Ellis-van Creveld syndrome: Dental, clinical, genetic and dermatoglyphic findings of a case. *J Clin Pediatr Dent.* 2000;24:141-145.
2. McKusick VA, Egeland JA, Eldridge R, Krusen DE. Dwarfism in the Amish. In: The Ellis-van Creveld syndrome. *Bull Johns Hopkins Hosp.* 1964;115:306-336.
3. Polymeropoulos MH, Ide SE, Wright M, et al. The gene for the Ellis-van Creveld syndrome is located on chromosome 4p16. *Genomics.* 1996;35:1-5.
4. Martínez Frias ML, Sanchez Cascos A. [Ellis-van Creveld syndrome]. *Rev Clin Esp.* 1974;133:311-318.
5. Hattab FN, Yassin OM, Sasa IS. Oral manifestations of Ellis-van Creveld syndrome: Report of 2 siblings with unusual dental anomalies. *J Clin Pediatr Dent.* 1998;22:159-165.
6. Oliveira da Silva E, Janovitz D, Cavalcanti S. Ellis-van Creveld syndrome: Report of 15 cases in an inbred kindred. *J Med Genet.* 1980;17:349-356.
7. Ortega J, Ferrer J, Fernández A, Iriando M, Manzanares R, Gean E. [The Ellis-van Creveld syndrome (chondroectodermal dysplasia): Apropos a clinical case.] *An Esp Pediatr.* 1999;50:74-76.

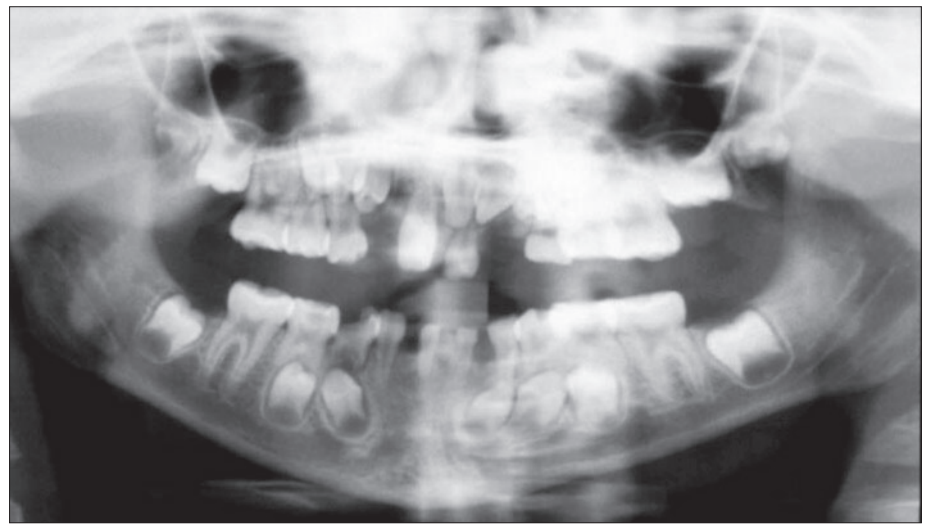


Figure 11. Panoramic radiograph demonstrating multiple congenitally absent anterior teeth, dysmorphic roots of lower incisors, and delayed eruption of upper left central incisor.

Table 3. Dental Management*

Clinical cases	1	2	3	4	5
Age at last examination	6	13	18	17	17
Dental treatment					
Fissure sealants	Y	N	Y	N	N
Restoration of carious teeth	Y	Y	Y	Y	N
Composite build-ups of abnormally shaped teeth	N	N	Y	N	N
Esthetic treatment					
Anterior acrylic partial dentures	N	Y	N	Y	N
Surgical treatment					
Surgery of fusion of upper lip to gingival margin	N	N	N	N	Y
Extraction of supernumerary teeth	N	N	Y	N	Y
Extraction of impacted teeth	N	N	N	N	Y
Orthodontic treatment	N	N	N	Y	Y
Prosthetic treatment					
Fixed bridgework	N	N	N	Y	N

*Y=yes; N=no.

8. Himelhoch DA, Mostofi R. Oral abnormalities in the Ellis-van Creveld syndrome: Case report. *Pediatr Dent.* 1988;10:309-313.
9. Pérez Alvarez F, Martínez Santana S, Rodríguez C. Ellis-van Creveld syndrome. *An Esp Pediatr.* 1982;17:223-228.
10. Sergi C, Voigtländer T, Zoubaa S, et al. Ellis-van Creveld syndrome: A generalized dysplasia of enchondral ossification. *Pediatr Radiol.* 2001;31:289-293.

11. Ruiz-Perez VL, Ide SE, Strom TM, et al: Mutations in a new gene in Ellis-van Creveld syndrome and Weyers acrorenal dysostosis. *Nat Genet.* 2000;24:283-286.
12. Ruiz-Perez VL, Tompson SWJ, Blair HJ, et al. Mutations in 2 nonhomologous genes in a head-to-head configuration cause Ellis-van Creveld syndrome. *Am J Hum Genet.* 2003;72:728-732.
13. Alcalde MM, Castillo JA, García Urruticoechea P, Vilaplana R, Molina E, Ortega J. Ellis-van Creveld syndrome: An easy early diagnosis? *Rev Esp Cariol.* 1998;51:407-409.
14. Guschmann M, Horn D, Gasiorek-Wiens A, Urban M, Kunze J, Vogel M. Ellis-van Creveld syndrome: Examination at 15 weeks' gestation. *Prenat Diagn.* 1999;19:879-883.
15. Prabhu SR, Daftary DK, Dholakia HM. Chondroectodermal dysplasia (Ellis-van Creveld syndrome): Report of 2 cases. *J Oral Surg.* 1978;36:631-637.
16. Hunter ML, Roberts GJ. Oral and dental anomalies in Ellis van Creveld syndrome (chondroectodermal dysplasia): Report of a case. *Int J Paediatr Dent.* 1998;8:153-157.
17. Varela M, Ramos C. Chondroectodermal dysplasia (Ellis-van Creveld syndrome): A case report. *Eur J Orthod.* 1996;18:313-318.
18. Susami T, Kuroda T, Yoshimasu H, Susuki R. Ellis-van Creveld syndrome: Craniofacial morphology and multidisciplinary treatment. *Cleft Palate Craniofac J.* 1999;36:345-352.
19. Fryns JP. Postaxial polydactyly as heterozygote manifestation in Ellis-van Creveld syndrome? (Comment) *Am J Med Genet.* 1991;39:500-501.
20. Goldblatt J, Minutillo C, Pemberton PJ, Hurst J. Ellis-van Creveld syndrome in a Western Australian aboriginal community: Postaxial polydactyly as a heterozygous manifestation? *Med J Aust.* 1992;157:271-272.

ABSTRACT OF THE SCIENTIFIC LITERATURE



TRANSPORT MEDIA FOR AVULSED PERMANENT TEETH

Avulsion injuries account for 16% of all traumatic injuries in the permanent dentition. The damage to the attachment apparatus is unavoidable, but maintaining the viability of the periodontal ligament is critical. Although immediate replantation has been shown to have the best prognosis, this rarely occurs. Therefore, the storage conditions should be designed to maximize preservation of the PDL. A recent study examined PDL cells exposed to various types of storage media: (1) culture media; (2) milk; (3) Hank's Balanced Salt Solution (HBSS); (4) contact lens solutions; and (5) Gatorade. The investigators found that significantly higher numbers of PDL cells survived and proliferated on ice than in room temperature. Water had a detrimental effect on PDL cells at either room temperature or on ice, whereas HBSS preserved the cells significantly more than any other solution. Contact lens solution and Gatorade preserved more cells than water at both temperatures.

Comments: These findings emphasize that HBSS is still the best transport media for an avulsed tooth. Cold milk was second, and contact lens solution and Gatorade also preserved cells. Water was detrimental to PDL cells. JYL

Address correspondence to Dr. Lynne Opperman, Department of Biomedical Sciences, Baylor College of Dentistry, Texas A&M University System Health Science Center, 3302 Gaston Ave., Dallas, TX 75246.

Siglas E, Regan JD, Kramer PR, et al. Survival of human periodontal ligament cells in media proposed for transport of avulsed teeth. *Dent Traumatol.* 2004;20:21-28.

58 references